

## Mammotome elite breast biopsy device

Mammotome elite 13 gauge successfully and accurately samples all lesions and reduces underestimation rate compared to a 14-gauge core needle for non-mass breast lesions under ultrasound guided breast biopsy<sup>1-6</sup>

---

Original Article:	<a href="#">Ultrasound-guided cable-free 13-gauge vacuum-assisted biopsy of non-mass breast lesions</a>
Journal:	<i>PLoS ONE</i>
Publication Date:	June 2017
Authors:	Jiwoon Seo <sup>1</sup> , Sun Mi Kim <sup>1*</sup> , Mijung Jang <sup>1</sup> , Bo La Yn <sup>1</sup> , Soo hyun Lee <sup>1</sup> , Eun-Kyu Kim <sup>2</sup> , Eunyong Kang <sup>2</sup> , So Yeon Park <sup>3</sup> , Woo Kyung Moon <sup>4</sup> , Hye Young Choi <sup>5</sup> , Bohyoung Kim <sup>6</sup>

---

### OBJECTIVE

The objective of this study was to compare the outcomes of ultrasound guided breast biopsy by Mammotome elite 13 gauge and conventional 14-gauge spring loaded core needle for patients with non-mass like lesions.

### METHODS

Investigators conducted a prospective study of patients with ultrasound detected non-mass like lesions to identify patients meeting the following criteria:

- Non-mass like lesions classified as BI-RADS category 4 or 5
- Non-mass like lesions with and without suspicious microcalcifications on ultrasound, correlated previously using mammography or via breast MRI

216 patients met these criteria. The study included 125 patients with 145 lesions classified as BI-RADS category 4 or 5.

Clinical, radiologic and pathologic data was correlated and analyzed to determine the success rate between the two devices.

Device of choice for biopsy was determined based on patients consent to use Mammotome elite (wireless VAB) in place of a 14-gauge spring loaded core needle.

### DISCUSSION

13-gauge Mammotome elite was able to accurately target lesions and improve pathologic diagnosis when compared to 14-gauge core needle.

- Mammotome elite as a hand-held, cable-free VAB system was able to access lesions accurately.
- Significant reduction in DCIS underestimation was observed with Mammotome elite breast biopsy device.
- No radiologic-pathologic discordance was observed with Mammotome elite during post-biopsy analysis of the samples.
- Mammotome elite provided larger tissue samples than the 14-gauge core needle.

Ultrasound-guided 13-gauge Mammotome elite was found to be superior in retrieval of microcalcifications visible under ultrasound for non-mass like lesions.

No major complications were observed during and after biopsies with both Mammotome elite and 14-gauge core needle (n=145)

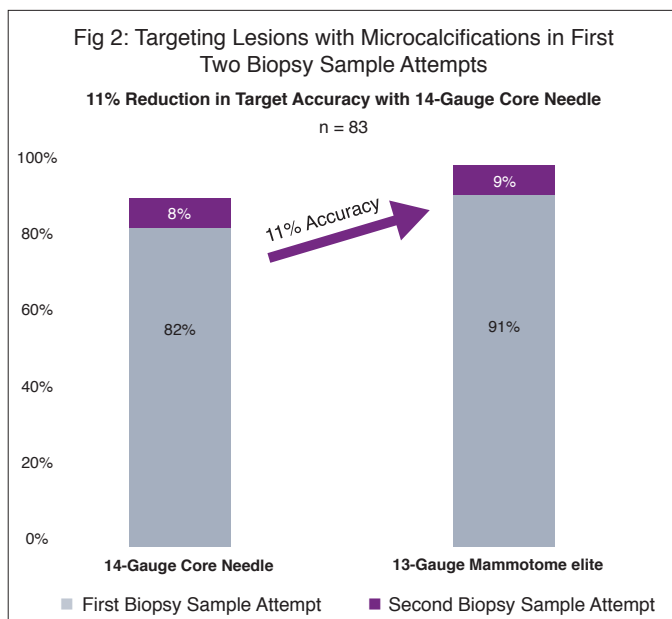
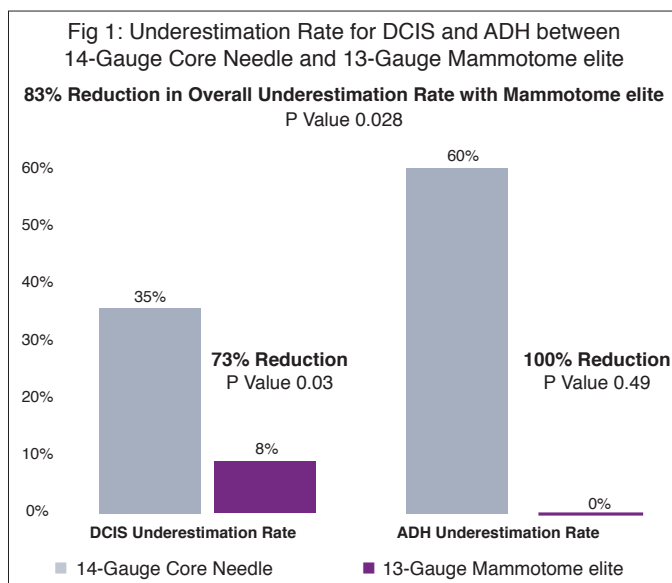
- Hematomas <3cm were observed on immediate post biopsy with both techniques.
- None of the patients developed hematomas or wound infections requiring treatment.
- Follow up of patients was limited to a week after biopsy and three months after biopsy.
- More tissue samples were easily obtained using Mammotome elite (avg. 9) in comparison to core needle (avg. 6) that helped in better histo-pathological correlation.

# Clinical Highlights

## RESULTS

During the 16-month study period, which included 145 lesions and 125 patients, the results were:

- 100% accuracy in sampling of target lesions using Mammotome elite breast biopsy device.
- 73% reduced underestimation of DCIS and ADH with Mammotome elite compared to 14-gauge core needle. (Fig 1)
- 0% radiologic-pathologic discordance was observed with Mammotome elite.
- 100% accuracy in targeting lesions with calcifications using Mammotome elite breast biopsy device.
- 25% increase in accuracy in targeting lesions with calcifications using 13-gauge Mammotome elite.(Fig 2)



## KEY POINTS

This landmark study demonstrates that the 13-gauge Mammotome elite improves targeting accuracy, reduces pathological discordance, and decreases the appearance of mammographic alterations of a core needle.<sup>7</sup>

The finding of hypoechoic area in ultrasound with microcalcification showed statistical significance in occurrence of malignant lesions and positive prediction for DCIS.

- Mammotome elite provided accuracy in sampling these lesions efficiently. Multiple studies have identified non-mass like lesions with and without calcifications to be visible under ultrasound for biopsy.<sup>7,8</sup>
- The frequency of malignancy tends to rise when calcifications associated with these lesions are visible under ultrasound.

This study examined the occurrence and visibility of non-mass like lesions under ultrasound and biopsy sample outcomes that prove the benefit of using 13-gauge Mammotome elite over a 14-gauge core needle.

## CONCLUSION

Mammotome elite is the leading single insertion, tetherless vacuum-assisted breast biopsy device for ultrasound-guided procedures. In addition to general ultrasound breast biopsy use on various lesion/mass types, Mammotome elite is also useful when suspicious nonpalpable, non-mass like lesions are visible under ultrasound with and without calcifications. Use of Mammotome elite improves accuracy and reduces false-negative biopsy results.

## ABOUT THE AUTHORS

1. Department of Radiology, Seoul National University Bundang Hospital, Seoul National University College of Medicine, Seoul, Republic of Korea
2. Department of Surgery, Seoul National University Bundang Hospital, Gyeonggi-do, Republic of Korea
3. Department of Pathology, Seoul National University Bundang Hospital, Gyeonggi-do, Republic of Korea
4. Department of Radiology, Seoul National University College of Medicine, Seoul National University Hospital, Seoul, Republic of Korea
5. Department of Radiology, Gyeongsang National University Hospital, Jinju-si, Republic of Korea
6. Division of Biomedical Engineering, Hankuk University of Foreign Studies, Oedae-ro 81, Mohyeon-myeon, Cheoin-gu, Yongin-si, Gyeonggi-do, Korea

## REFERENCES

7. Boo-Kyung Han., et al., Initial Experience with a Wireless Ultrasound-Guided Vacuum-Assisted Breast Biopsy Device. PLoS ONE 10(12):e0144046
8. Z.L.Wang., et al., Non-mass like lesions on breast ultrasound: classification and correlation with histology, Italian Society of Medical Radiology 2015